

Original Article

Open lung biopsy in patients on mechanical ventilation and presenting diffuse pulmonary infiltrate*

ANDREIA SALARINI MONTEIRO**, GABRIELA ADDOR, DAVID HENRIQUE NIGRI,
CARLOS ALBERTO DE BARROS FRANCO**

Background: Open lung biopsy is regarded as the gold standard for the diagnosis of diffuse pulmonary infiltrates.

Objective: To determine the diagnostic yield, therapeutic changes, complications and mortality attributed to open lung biopsy in patients with diffuse pulmonary infiltrates and on mechanical ventilation.

Method: We reviewed, retrospectively, the charts of 24 patients, ranging from 26 to 89 years of age, admitted to the intensive care units of two private hospitals and submitted to open lung biopsy.

Results: Diagnostic positivity was found in 100% of patients, resulting in an alteration in the treatment regimen in 75%. Postoperative complications occurred in five patients (20.8%). There were no biopsy-related deaths, although global mortality was 45.8%.

Conclusion: Open lung biopsy is a safe and high yield procedure for diagnosing diffuse pulmonary infiltrate in patients on mechanical ventilation. Despite the fact that no mortality impact factor has been assigned to such patients, data in the literature regarding prognosis must be taken into consideration.

J Bras Pneumol 2005; 31(3): 212-8.

Key words: Biopsy. Respiratory insufficiency. Respiration artificial.

* Study conducted in the Pulmonology Department of the Postgraduate School of Medicine of the Pontificia Universidade Católica in Rio de Janeiro - PUCRJ

**Specialist, as designated by the Sociedade Brasileira de Pneumologia e Tisiologia.

Correspondence to: Andreia Salarini Monteiro. Rua Sorocaba 464 / 402 Botafogo. CEP: 22271-110, Rio de Janeiro, RJ.

Phone: 55 21 2266-7392. E-mail: andreamonteiro@domain.com.br e respirar@pobox.com

Submitted: 30 May 2005. Accepted, after review: 25 February 2005.

INTRODUCTION

Lung biopsy is an invasive diagnostic procedure and is normally used when other, less-invasive procedures have failed to yield a definitive diagnosis or when a rapid and precise diagnosis is needed^(1,2).

Lung biopsy through thoracotomy, or open lung biopsy (OLB), allows the surgeon to obtain tissue fragments appropriate for efficient histological, histochemical and even molecular analysis, which is becoming more specialized and allows a more accurate diagnosis. Performed under general anesthesia, OLB requires postoperative pleural drainage for at least 24 hours. A small access incision (minithoracotomy) is used, with no need for resection of the costal arch. The site of choice for conducting the procedure depends on the radiological findings. In cases of diffuse infiltrate, biopsies from one or more sites may be needed⁽¹⁾.

Recommending OLB for critical intensive care unit patients on mechanical ventilation is a difficult decision. The progression of the disease, combined with the need to institute a specific treatment, is an important factor. In such cases, OLB-related morbidity and mortality seem to be minimal⁽¹⁾.

The aim of this study was to evaluate the diagnostic yield, changes in treatment strategy, complications and mortality among patients on mechanical ventilation who presented diffuse pulmonary infiltrate and were submitted to OLB.

METHODS

This was a retrospective study evaluating patients suffering from diffuse pulmonary infiltrate that evolved to acute respiratory insufficiency. These patients were on mechanical ventilation and were submitted to OLB in order to elucidate the diagnosis.

The study was conducted from September 1987 to September 2002 and involved patients admitted to the intensive care units of two private hospitals.

A total of 24 patients were included. These patients had previously been submitted to fiberoptic bronchoscopy, which had resulted in no definitive diagnosis and, in some cases, despite the treatment instituted (antibiotic therapy based on culture results), was followed by progressive worsening.

In 13 patients (54.2%), the OLB was conducted in an operating room. In the remaining 11 patients (45.8%), the procedure was carried out in the intensive care unit itself due to the high risk involved in transporting those patients.

The biopsies were conducted by different chest surgeons, under general anesthesia and using minithoracotomy. In all cases, suture of the lung was performed with surgical staples.

A fragment of lung tissue was obtained from the site presenting the greatest degree of involvement in the computed tomography scan of the chest. In all cases, a pathologist was present at the time of the procedure in order to evaluate the quality of the material obtained. The material was then sent for histopathological study, direct exam and culture (for pyogenic germs, mycobacteria and fungi), immunofluorescence for atypical germs (*Legionella sp.*, *Mycoplasma sp.* and *Chlamydia sp.*) and, in suspect cases, for virus culture (using HEp2 cells in Eagle Hanks medium supplemented with bovine fetal serum).

RESULTS

A total of 24 patients (12 men and 12 women) were included in the study (Table 1). The mean age was 65.9 years (range, 26 to 89).

A total of 11 patients (45.8%) were considered immunocompromised (7 suffered from malignant neoplasia, 3 made chronic use of corticosteroids, and 1 presented both characteristics).

The conduction of OLB in this group of patients, OLB resulted in diagnosis in 100% of the cases (Table 2).

Two patients presented more than one diagnosis: one presented acute respiratory distress syndrome (ARDS) accompanied by pneumococcal pneumonia, whereas the other presented ARDS accompanied by pneumonia caused by *Pneumocystis carinii*.

One patient was diagnosed with primary lung neoplasia (small cell carcinoma), 1 with undifferentiated metastatic carcinoma, 6 with ARDS, 1 with acute interstitial pneumonitis (Hamman-Rich syndrome), 2 with desquamative interstitial pneumonia, 2 with usual interstitial pneumonitis (idiopathic pulmonary fibrosis), 4 with pneumonitis caused by drugs, 2 with Churg-Strauss vasculitis and 6 with infection (2 due to *P. carinii*, 1 due to *Streptococcus pneumoniae*, 1 due to *Legionella sp.*, 1 by *Mycoplasma sp.*, and 1 in which the etiological agent was not identified). The diagnoses of pneumonia due to *Mycoplasma sp.* and *Legionella sp.* were made using immunofluorescence of the biopsy samples, whereas the diagnosis of pneumococcal pneumonia was made through tissue culture (Figure 1).

TABLE 1

Patients included in the evaluation

Patient	Gender	Age	Diagnosis at ICU Admission
1	Male	87	Adenovirus Pneumonia
2	Female	75	Lung squamous cell carcinoma + diffuse interstitial infiltrate
3	Female	80	Pneumonia caused by <i>Chlamydia sp.</i>
4	Female	44	Community-acquired pneumonia caused by <i>Mycoplasma sp.</i> + corticosteroid use
5	Male	84	Bronchial aspiration in abdominal surgery postoperative period
6	Male	70	Severe community-acquired pneumonia
7	Male	86	Severe community-acquired pneumonia
8	Female	77	Diffuse interstitial infiltrate
9	Male	29	Severe community-acquired pneumonia
10	Female	66	Diffuse interstitial infiltrate
11	Male	69	Non-Hodgkin's lymphoma
12	Male	58	Idiopathic pulmonary fibrosis + corticosteroid use
13	Male	59	Bladder Carcinoma and Taxol use + pneumonia
14	Male	83	Rheumatoid arthritis + pulmonary fibrosis
15	Female	49	Severe community-acquired pneumonia
16	Female	82	Idiopathic pulmonary fibrosis + corticosteroid use
17	Female	75	COPD + multiple myeloma + Diffuse pulmonary infiltrate
18	Female	60	Non-Hodgkin's lymphoma
19	Female	26	Severe community-acquired pneumonia
20	Female	59	Diffuse interstitial infiltrate
21	Male	89	Severe community-acquired pneumonia
22	Male	72	Fungal infection
23	Male	47	Multiform glioblastoma + use of corticosteroid + pneumonia caused by <i>P. carinii</i> + diffuse interstitial infiltrate
24	Female	56	Lung adenocarcinoma + chemotherapy

ICU: intensive care unit; COPD: chronic obstructive pulmonary disease

Five patients (20.8%) presented complications related to the procedure: 1 with pleural empyema due to *Staphylococcus aureus* and 4 with bronchopleural fistula. Of the 4 patients who developed bronchopleural fistula, 3 were diagnosed with ARDS.

There were no deaths directly related to the diagnostic procedure.

After the results of the OLB were known, there was a treatment strategy change, defined as the introduction or withdrawal of a particular drug, in 18 cases (75%). Global mortality, during the hospitalization period in the intensive care unit was 45.8% (11 patients) (Figure 2). One of the deaths occurred due to the progression of the underlying disease (multiform glioblastoma) after reduction of the pulmonary infiltrate. A total of 13 patients were discharged from the intensive care unit and were later discharged from the hospital (54.2%).

Among the 11 patients who died, the treatment regimen was not changed after the OLB in 5 (45.4%).

In contrast, among the 13 (54.2%) who survived, the treatment remained unchanged in only 1 (7.7%).

Eleven patients (45.8%) were considered immunocompromised, of which 7 (63.6%) underwent a change in treatment and 3 (27.2%) presented complications. Of those 11, 8 (72.7%) died.

Of the 13 immunocompetent patients (54.2% of the cases), 11 (84.6%) underwent a change in treatment, 2 (15.3%) presented complications and 3 (23%) died.

DISCUSSION

It is rare for OLB to be performed in an intensive care unit, the annual incidence in the USA ranging from 0% to 0.9%(4). Despite the fact that these patients were all in critical condition, the procedure proved safe and provided high positivity for the diagnosis of diffuse pulmonary infiltrate^(4,5). The decision to perform OLB in patients on mechanical ventilation is made based on the need to obtain a precise diagnosis and

TABLE 2

Diagnosis and evolution after OLB

Patient	Diagnosis after OLB	Change in treatment	Outcome
1	Idiopathic pulmonary fibrosis	No	Death
2	Pneumonitis caused by drug use	No	Death
3	Desquamative interstitial pneumonia	Yes	Discharge
4	ARDS	Yes	Discharge
5	ARDS	Yes	Discharge
6	ARDS + pneumonia caused by pneumococci	Yes	Discharge
7	Infectious pneumonia	No	Discharge
8	Churg-Strauss syndrome	Yes	Discharge
9	Pneumonia caused by <i>Mycoplasma sp.</i>	Yes	Discharge
10	Desquamative interstitial pneumonia	Yes	Discharge
11	Small cell carcinoma	No	Death
12	Idiopathic pulmonary fibrosis	No	Death
13	Pneumonitis caused by drug use	Yes	Death
14	ARDS	Yes	Death
15	Pneumonia caused by <i>Legionella sp.</i>	Yes	Discharge
16	Idiopathic pulmonary fibrosis	Yes	Discharge
17	ARDS + pneumonia caused by <i>P. carinii</i>	Yes	Death
18	Pneumonitis caused by drug use	Yes	Death
19	Pneumonia caused by <i>P. carinii</i>	Yes	Discharge
20	Poorly differentiated carcinoma metastasis	No	Death
21	Acute interstitial pneumonia (Hamman-Rich)	Yes	Death
22	Churg-Strauss syndrome	Yes	Discharge
23	ARDS	Yes	Death
24	Pneumonitis caused by drug use	Yes	Discharge

OLB: open lung biopsy; ARDS: acute respiratory distress syndrome

therefore offer specific treatment (avoiding the harmful effects or inefficiency of empirical treatment) or even on the desire to obtain prognostic information^(4,6).

There is no consensus regarding the timing of the OLB^(4,7,8). The biopsy site should be determined based on the radiological findings so that only a small fragment need be collected^(9,10). Biopsy samples taken from the lingula or medial lobe yield results equivalent to those taken from other sites^(9,11,12). To be adequate for histological and bacteriological analysis, the tissue sample should measure at least 3 x 2 x 1 cm^(3,13).

Despite their similar efficiency, OLB was chosen over video-assisted thoracoscopy in these patients due to the shorter time needed for conducting the procedure, together with the fact that there was neither the need to change the orotracheal tube to one with a double lumen nor the need to selectively ventilate one lung^(7,14-16).

For the diagnosis of diffuse pulmonary infiltrate, OLB is regarded as the gold standard^(1,4,7-9,17). In the literature, its positivity varies from 80% to 94%, whereas that of procedures using fiberoptic bronchoscopy (bronchoalveolar lavage, bronchial brush and transbronchial biopsy) ranges from 38% to 85%(4). Transbronchial biopsy in patients on mechanical ventilation may be safely conducted, although its diagnostic efficiency is only 48%, with no significant improvement even when the number of collected tissue samples is doubled⁽¹⁸⁻²⁰⁾.

Diagnostic positivity in our study was 100%, and only two patients presented more than one concomitant diagnosis (8.3% of the cases). Flabouris et al.⁽⁴⁾ also studied 24 patients with respiratory insufficiency, on mechanical ventilation and submitted to OLB and found 92% diagnostic positivity (the histopathology was normal in 8% of the cases). Canver et al.⁽²¹⁾

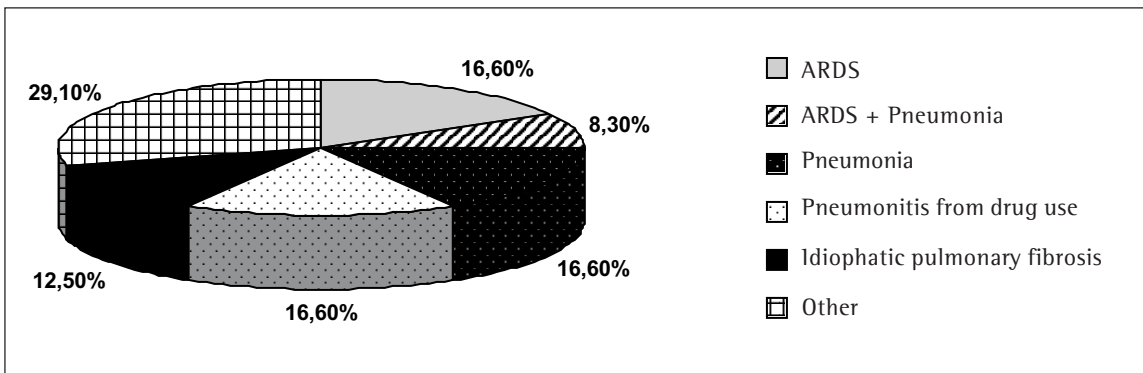


Figure 1. Diagnoses after open lung biopsy

evaluated 27 respiratory insufficiency patients on mechanical ventilation and found OLB to present 100% positivity. Diagnostic positivity of OLB in patients on mechanical ventilation is comparable to that found in patients with diffuse pulmonary infiltrate and not on ventilatory support^(9,10,22).

Based on the OLB results, treatment regimens were adjusted in 18 cases (75%), in full concordance with the results obtained by Flabouris *et al.*⁽⁴⁾ and comparable to the 67% found by Canver *et al.*⁽²¹⁾ (67%).

Atelectasis, bronchopleural fistula, empyema and hemothorax have all been associated with OLB^(1,4,7-9). Five of our patients (20.8%) presented such complications, bronchopleural fistula being the most common (4 cases). Flabouris *et al.*⁽⁴⁾ reported complications in 17% of patients and prolonged air leakage in all patients. One of the

patients presented excessive bleeding in the immediate postoperative period, requiring surgical reintervention and dying some hours later. Canver *et al.*⁽²¹⁾ observed complications in 40% of patients, prolonged air leakage being the most frequent. Being on mechanical ventilation does not seem to increase the frequency of complications. In the studies reviewed, in which patients with diffuse pulmonary infiltrate and not on mechanical ventilation were submitted to OLB and subsequently evaluated, complications were observed in less than 18%^(8,23-26). Most patients who presented complications were diagnosed with ARDS. Chuang *et al.*⁽²⁷⁾ observed a higher frequency of complications in patients with ARDS. Patel *et al.*⁽²⁸⁾ recently published a study involving 57 patients with ARDS who underwent OLB and showed the frequency of complications to be 39%,

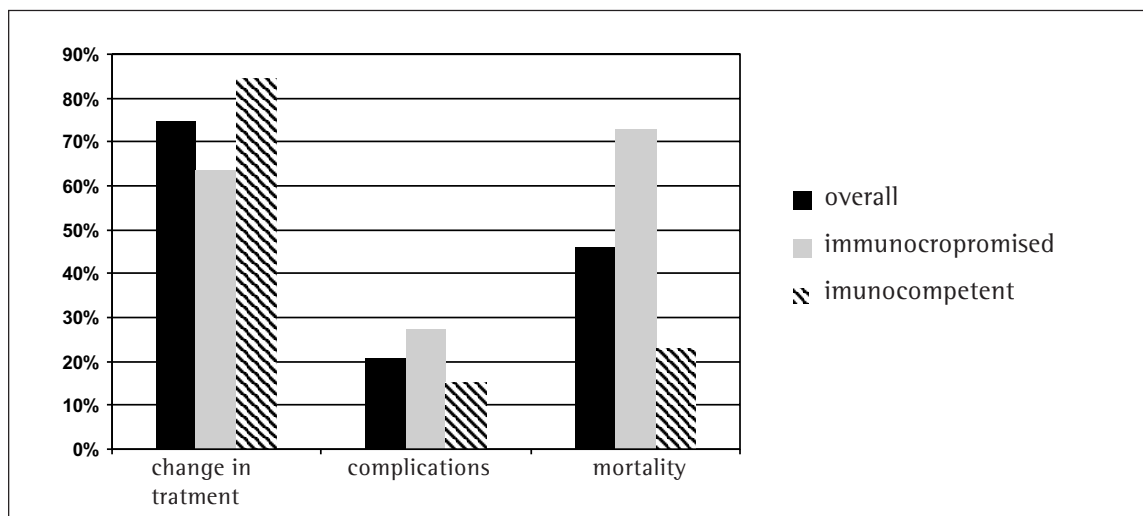



Figure 2. Clinical evolution of patients submitted to open lung biopsy

a result similar to those published by other authors^(21,28).

Intraoperative mortality in the present study was 0%. This is in agreement with reports from other authors, including those who evaluated patients with diffuse pulmonary infiltrate and not on mechanical ventilation^(4,7-9,22).

Global mortality in the present study was 45.8%, lower than the 67% and 52% found by other authors^(4,21). Of the patients who survived, post-OLB changes in treatment were made in 92.3% of cases (Table 3). Flabouris et al.⁽⁴⁾ observed that treatment regimens had been changed for 88% of the survivors, and the chi-square test showed a strong, albeit less than significant, tendency toward lower mortality when treatment regimens were changed based on OLB findings.

In the present study, the mortality rate among patients considered immunocompromised was higher than that observed in immunocompetent patients (72.7% and 27.2%, respectively), in contrast to the findings of Walker et al.⁽⁸⁾ and Wagner et al.⁽²²⁾, who found no such difference. This difference in mortality may be explained by of the fact that the patients in the present study were in more critical condition since the authors cited above evaluated immunocompromised patients with diffuse pulmonary infiltrate that were not on mechanical ventilation.

The most common diagnoses among our patients were ARDS (6 cases; 25%) and pneumonia (6 cases; 25%). Corticosteroid therapy was initiated in four patients who presented ARDS phases 2 and 3 and after associated infection had been disregarded. In the other two patients diagnosed with ARDS, corticosteroid therapy was initiated in association with the treatment for pneumonia due to *P. carinii*, defined as PaO₂ < 70 mmHg. The diagnosis of bacterial pneumonia was made through tissue culture in only one case (4.1%). The positivity of lung tissue culture is normally low, varying from 0% to 4% in the literature⁽⁹⁾.

We can conclude that OLB is a procedure presenting low mortality and morbidity and may be safely conducted in patients on mechanical ventilation. The impact of OLB on the mortality of these patients has not yet been established in the literature. However, of the methods available for evaluating such patients, OLB presents the highest diagnostic positivity.

The benefit of OLB should be evaluated not only in terms of improving median survival but also in view of the valuable prognostic information obtained.

REFERENCES

- Rippe JM. Lung biopsy. In: Chorpensing NE, Stuart RJ, editors. Intensive Care Medicine. 3th ed. New York: Little, Brown and Company; 1996: p.923-32.
- Robbins BE, Steiger Z, Wilson RF, Ratanath V, Karanes C, Bander J, et al. Diagnosis of acute diffuse pulmonary infiltrates in immunosuppressed patients by open biopsy of the lung. Surg Gynecol Obstet 1992; 175: 8-12.
- Shields TW. Laboratory investigations in the diagnosis of pulmonary diseases. In: McQueen JB, editor. General thoracic surgery. 5th ed. Philadelphia: Lippincott Williams & Wilkins; 2000: 225-41.
- Flabouris A, Myburgh J. The utility of open lung biopsy in patients requiring mechanical ventilation. Chest 1999; 115: 811-7.
- Papazian L, Thomas P, Bregeon F, Garbe L, Zandotti C, Saux P, et al. Open-lung biopsy in patients with acute respiratory distress syndrome. Anesthesiology 1998; 88: 935-44.
- Janz TG, Madam R, Marini JJ, Summer WR, Meduri GU, Smith RM, et al. Clinical conference on management dilemmas: progressive infiltrates and respiratory failure. Chest 2000; 117: 562-72.
- Warner DO, Warner MA, Divertie MB. Open lung biopsy in patients with pulmonary infiltrates and acute respiratory failure. Am Rev Resp Dis 1998; 137: 90-4.
- Walker WA, Cole FH, Khandekar AK, Mahfood SS, Watson DC. Does open lung biopsy affect treatment in patients with diffuse pulmonary infiltrates? J Thorac Cardiovasc Surg 1989; 97: 534-40.
- Temes RT, Joste NE, Allen NL, Crowell RE, Dox HA, Wernly JA. The lingula is an appropriate site for lung biopsy. Ann Thorac Surg 2000; 69: 1016-9.
- Chechani V, Landreneau R, Shaikh. Open lung biopsy for diffuse infiltrative lung disease. Ann Thorac Surg 1992; 54: 296-300.
- Miller RR, Nelems B, Muller NL, Evans KG, Ostrow DN. Lingular and right middle lobe biopsy in the assessment of diffuse lung disease. Ann Thorac Surg 1987; 44: 269-73.
- Temes RT, Joste NE, Qualls CR, Allen NL, Crowell RE, Dox HA, et al. Lung biopsy: is it necessary? J Thorac Cardiovasc Surg 1999; 118: 1097-100.
- Qureshi RA, Ahmed TA, Grayson AD, Soorae AS, Drakeley MJ, Page RD. Does lung biopsy help patients with interstitial lung disease? Eur J Cardio-thorac Surg 2002; 21: 621-6.
- Ferson PF, Landreneau RJ, Dowling RD, Hazelrigg SR, Ritter P, Nunchuck S, et al. Comparison of open versus thoracoscopic lung biopsy for diffuse infiltrative pulmonary disease. J Thorac Cardiovasc Surg 1993; 106: 194-9.
- Bensard DD, McIntyre RC, Waring BJ, Simon JS. Comparison of video thoracoscopic lung biopsy to open lung biopsy in the diagnosis of interstitial lung disease. Chest 1993; 103: 765-70.
- Kadokura M, Colby TV, Myers JL, Allen MS, Deschamps C, Trastek VF, et al. Pathologic comparison of video-assisted

- thoracic surgical lung biopsy with traditional open lung biopsy. *J Thorac Cardiovasc Surg* 1995; 109: 494-8.
17. Utz JP, Perrella MA, Rosenow EC. Lung Biopsy. *Adv Intern Méd* 1992; 37: 337-61.
 18. Rao VK, Ritter J, Kollef MH. Utility of transbronchial biopsy in patients with acute respiratory failure. *Chest* 1998; 114: 549-55.
 19. O'Brien JD, Ettinger NA, Shevlin D, Kollef MH. Safety and yield of transbronchial biopsy in mechanically ventilated patients. *Crit Care Med* 1997; 25: 440-6.
 20. Papin TA, Grum CM, Weg JG. Transbronchial biopsy during mechanical ventilation. *Chest* 1986; 89: 168-70.
 21. Canver CC, Mentzer Jr. RM. The role of open lung biopsy in early and late survival of ventilator-dependent patients with diffuse idiopathic lung disease. *J Cardiovasc Surg* 1994; 35: 151-5.
 22. Wagner JD, Stahler C, Knox S, Brinton M, Knecht B. Clinical utility of open lung biopsy for undiagnosed pulmonary infiltrates. *The Am J Surg* 1992; 164: 104-8.
 23. Jaffe JP, Maki DG. Lung biopsy in immunocompromised patients – one institution's experience and an approach to management of pulmonary disease in the compromised host. *Cancer* 1981; 48: 1144-53.
 24. Cheson BD, Samlowski WE, Tang TT, Spruance SL. Value of open-lung biopsy in 87 immunocompromised patients with pulmonary infiltrates. *Cancer* 1985; 55: 453-9.
 25. Canham EM, Kennedy TC, Merrick TA. Unexplained pulmonary infiltrates in the compromised patient – an invasive investigation in a consecutive series. *Cancer* 1983; 52: 325-9.
 26. Kramer MR, Berkman N, Mintz B, Godfrey S, Saute M, Amir G. The role of open lung biopsy in the management and outcome of patients with diffuse lung disease. *Ann Thorac Surg* 1998; 65: 198-202.
 27. Chuang ML, Lin IF, Tsai YH, Vintch JRE, Pang LC. The utility of open lung biopsy in patients with diffuse pulmonary infiltrates as related to respiratory distress, its impact on decision making by urgent intervention, and the diagnostic accuracy based on the biopsy location. *J Intensive Care Med* 2003; 18: 21-8.
 28. Patel SR, Karpaliotis D, Ayas NT, Mark EJ, Wain J, Thompson BT, et al. The role of open-lung biopsy in ARDS. *Chest* 2004; 125: 197-202.