

Chapter 7 – Zygomycosis*

Capítulo 7 – Zigomicose

Cecília Bittencourt Severo, Luciana Silva Guazzelli, Luiz Carlos Severo

Abstract

Zygomycosis (mucormycosis) is a rare but highly invasive infection caused by fungi belonging to the order Mucorales, which includes the genera *Rhizopus*, *Mucor*, *Rhizomucor*, *Absidia*, *Apophysomyces*, *Saksenaea*, *Cunninghamella*, *Cokeromyces* and *Syncephalastrum*. This type of infection is usually associated with hematologic diseases, diabetic ketoacidosis and organ transplantation. The most common form of presentation is rhinocerebral mucormycosis, with or without pulmonary involvement. Pulmonary zygomycosis is more common in patients with profound, prolonged neutropenia and can present as segmental or lobar infiltrates, isolated nodules, cavitary lesions, hemorrhage or infarction. The clinical and radiological manifestations are often indistinguishable from those associated with invasive aspergillosis. This article describes the general characteristics of pulmonary zygomycosis, emphasizing laboratory diagnosis, and illustrates the morphology of some lesions.

Keywords: Zygomycosis; Diagnostic techniques and procedures; Mucormycosis.

Resumo

A zigomicose (mucormicose) é uma infecção rara, mas altamente invasiva, causada por fungos da ordem Mucorales (gêneros *Rhizopus*, *Mucor*, *Rhizomucor*, *Absidia*, *Apophysomyces*, *Saksenaea*, *Cunninghamella*, *Cokeromyces* e *Syncephalastrum*). Esse tipo de infecção é usualmente associado a doenças hematológicas, cetoacidose diabética e transplante de órgãos. A apresentação clínica mais frequente é a mucormicose rinocerebral, com ou sem envolvimento pulmonar. A zigomicose pulmonar ocorre mais frequentemente em pacientes com neutropenia profunda e prolongada e pode se apresentar como infiltrado lobar ou segmentar, nódulos isolados, lesões cavitárias, hemorragia ou infarto. As manifestações clínicas e radiológicas são na maioria dos casos indistinguíveis daquelas associadas com aspergilose invasiva. Este artigo descreve as características gerais da zigomicose pulmonar, com ênfase no diagnóstico laboratorial, e ilustra a morfologia de algumas lesões.

Descritores: Zigomicose; Técnicas de diagnóstico e procedimentos; Mucormicose.

Introduction

Zygomycosis is an uncommon fungal infection caused by fungi of the class Zygomycetes, order Mucorales and Entomophthorales. Entomophthoromycosis usually presents as a subcutaneous infections, occurring in tropical areas. Mucormycosis is caused by opportunistic pathogens, mainly resulting in processes that lead to neutropenia or neutrophil dysfunction. Rarely does it generate disease in immunocompetent patients. Mucormycosis is the third most common invasive fungal infection, following aspergillosis and candidiasis, and accounts for 8.3-13.0% of all fungal infections found in autopsies of hematologic patients.⁽¹⁻⁶⁾

In mucormycosis, the most common fungal genus is *Rhizopus*; however, other organisms associated with human infection belong to the genus *Mucor*, *Rhizomucor*, *Absidia*, *Apophysomyces*, *Saksenaea*, *Cunninghamella*, *Cokeromyces* and *Syncephalastrum*.^(7,8) The clinical presentation correlates with the predisposing conditions of the host (Table 1). The clinical course and progression of the disease are typically fulminant due to rapid fungal growth and concomitant tissue destruction, which requires early diagnosis as well as prompt clinical and surgical treatment.⁽⁸⁾ Most cases occur in patients with leukemia. Regarding rhinocerebral mucormycosis, the patient characteristically has

* Study carried out at the Mycology Laboratory of the Santa Rita Hospital, Santa Casa Hospital Complex, and at the *Universidade Federal do Rio Grande do Sul* – UFRGS, Federal University of Rio Grande do Sul – Porto Alegre, Brazil.

Correspondence to: L.C. Severo. Laboratório de Micologia, Hospital Santa Rita, Santa Casa - Complexo Hospitalar, Rua Professor Annes Dias, 285, CEP 90020-090, Porto Alegre, RS, Brasil.

Tel 55 51 3214-8409. Fax 55 51 3214-8435. E-mail: severo@santacasa.tche.br or severo@pesquisador.cnpq.br

Financial support: None.

Submitted: 3 August 2009. Accepted, after review: 5 August 2009.

diabetes and ketoacidosis, which, in Brazil, constitutes the principal reported manifestation of mycosis. However, studies are incomplete, since they do not indicate the etiologic agent.⁽⁸⁾

The pulmonary manifestations occur in patients with cancer or in those submitted to bone marrow transplantation, whereas cerebral and disseminated infections predominate in intravenous drug abusers and in patients receiving deferoxamine.⁽⁹⁾

Mucormycosis is less common in patients with AIDS because T cell-mediated immunity is not considered an important factor for triggering the infection.⁽²⁾

The review of clinical and radiological aspects of mucormycosis, as well as of its diagnosis and treatment, with emphasis on its pulmonary manifestation, has motivated the present study.

Pulmonary mucormycosis

The lung is the second site most affected by mucormycosis, and inhalation of spores is the main route of infection.⁽⁷⁾ The clinical presentation is indistinguishable from that of invasive pulmonary aspergillosis. Patients with leukemia and lymphoma account for most of the cases (37%), followed by patients with diabetes mellitus (32%).⁽¹⁰⁾ This high prevalence might be related to the large number of patients with diabetes, compared with the number of those with malignant hematologic diseases. Leukemia, lymphoma, multiple myeloma and severe neutropenia increase the risk of developing pulmonary mucormycosis when these diseases are related to the other clinical presentations of the mycosis.⁽¹⁾ Patients with solid tumors rarely develop pulmonary mucormycosis.^(1,10-13)

Mucormycosis can develop in the lungs as a result of inhalation of infected material and through hematogenous or lymphatic dissemination. Frequently, if patients are not treated, there is hematogenous dissemination to other organs, particularly to the brain, resulting in death within 2-3 weeks.^(8,12)

Clinical findings

The clinical manifestations are nonspecific: cough; fever (> 38°C); dyspnea; sputum production; weight loss; hemoptysis; and chest pain.⁽³⁾ Hematologic patients can be co-infected with species of *Aspergillus* sp., *Candida* sp., cytomegalovirus and bacteria. In addition, bacteria are the reason for the occasional occurrence of an initial response to antibiotic therapy. Patients with diabetes have a tendency to develop endobronchial lesions. However, in the absence of this predisposing condition, the manifestation becomes less common. Among the signs, we can include hoarseness, hemoptysis, mediastinal enlargement and atelectasis.⁽¹⁾

Zygomycetes have marked vascular tropism, causing thrombosis and ischemic necrosis. Consequently, hemoptysis appears as a late finding, which can be fatal if cavitation is located in the innermost area of the lungs, since it affects large diameter vessels. In such cases, surgical resection is mandatory.⁽¹⁾

Pulmonary mucormycosis is uncommon in immunocompetent hosts. When infection occurs in apparently healthy individuals, its course is not so acute. Such patients can have cavitated lesions, infiltrates or slow-progressing nodules, accompanied by fever and dry cough.⁽¹⁾

In hematologic patients with focal pulmonary infection, the mortality rate ranges from 60 to 100%, and surgical resection can mean the difference between life and death. The method of treatment most often used is the combination of surgery and therapy with amphotericin B.^(1,3)

Radiological diagnosis

Conventional radiological techniques are of little use in the diagnosis of zygomycosis.⁽⁸⁾ The use of HRCT and, more particularly, the use of magnetic resonance imaging are extremely useful for the diagnosis of rhinocerebral, pulmonary and disseminated zygomycosis. Chest CT scans can identify infiltrates suggestive

Table 1 - Clinical presentation and predisposing factors.

Clinical presentation	Predisposing factors
Rhinocerebral	Diabetic ketoacidosis
Pulmonary	Granulocytopenia, lymphoma, leukemia, corticosteroid therapy, diabetes
Gastrointestinal	Severe malnutrition
Cutaneous	Severe burns, cutaneous trauma
Disseminated	Use of deferoxamine, hematologic diseases, diabetes, organ transplantation

of mucormycosis, and which were not detected on chest X-rays.^(14,15)

In pulmonary mucormycosis, the lesions often occur in the upper segments of the upper lobes of the lungs.⁽¹⁵⁾ Using conventional radiological techniques, the findings of pulmonary mucormycosis are similar to those of invasive aspergillosis.⁽¹⁾ Both infections have a propensity to exhibit angiotropism and to cause thrombosis.⁽¹⁶⁾

Tomographic findings demonstrate wedge-shaped infiltrates or consolidations and masses.⁽³⁾ Consolidations are present in approximately 66% of cases, whereas cavitations are present in 40% (Figure 1).^(1,3) The halo sign with ground-glass opacity, surrounding the pulmonary nodule, represents hemorrhage and edema, and can develop before and after the neutropenic phase.^(1,17) Pleural effusion and multiple nodular pulmonary infiltrates (more than 10) are independent predictors of zygomycosis.^(13,18) Chest HRCT can be sensitive in 26% of unsuspected lesions.^(15,19)

Disseminated zygomycosis can begin in the lungs and then proceed to invade more than two noncontiguous organs. Disseminated lesions in the central nervous system, in the liver and in the kidneys are common, causing multiple thromboembolism and areas of necrosis. Radiological findings vary depending on the organs invaded by *Zygomycetes*.^(1,3,15)

In the brain, the infarcted region presents a hypodense image with areas of hemorrhage and

a mass-like aspect. Although HRCT is essential, in some cases, it is necessary to complete the investigation with magnetic resonance imaging in order to determine the exact location of the affected area, when surgical treatment is necessary, especially in cases of brain abscess.^(1,20)

Laboratory diagnosis

The diagnosis is made based on the correlation among mycological examinations, histopathological examinations and clinical manifestations.^(8,10) Since this is the most fulminating mycosis, rapid diagnosis is extremely important for management and therapy to be successful. Unfortunately, there are few fungal elements. Therefore, this diagnosis is ultimately supported only by clinical evidence.⁽²¹⁾ Since *Zygomycetes* spores are common in the environment, direct examination to identify the organism is crucial in order for culture to be given weight. However, isolated culture is highly valid in patients with diabetes or neutropenia.

The diagnosis of mucormycosis is rarely suspected in hematologic patients due to the fact that physicians make a presumptive diagnosis of invasive aspergillosis. In hematologic patients, the diagnosis in life is made in only 23-50% of cases.⁽⁴⁾

Due to the clinical similarity between zygomycosis and other diseases caused by filamentous fungi, as well as due to the difficulty in making a specific diagnosis, many cases of

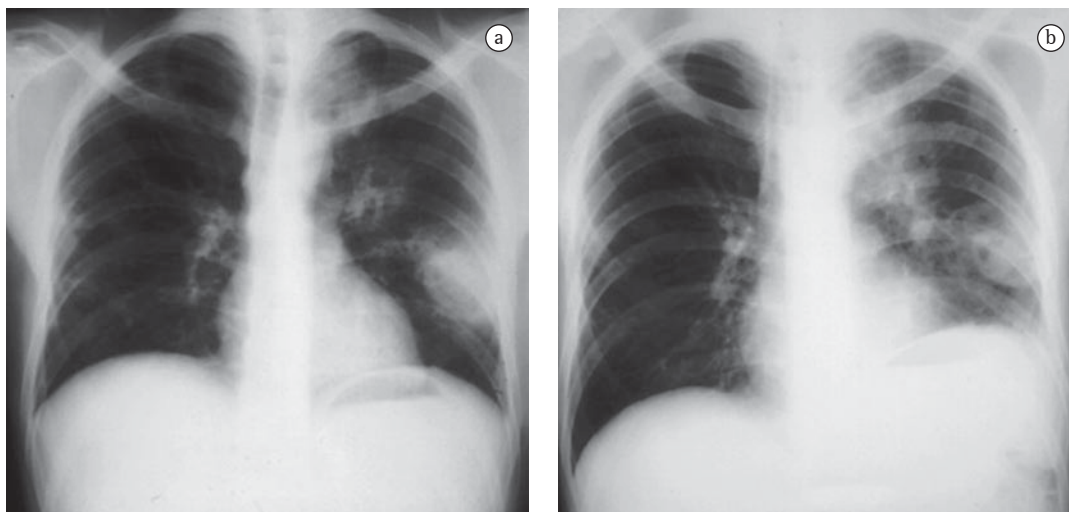


Figure 1 - Chest X-ray of a patient with leukemia showing cavitation (in a) and pulmonary consolidation (in b) by *Rhizomucor pusillus*.

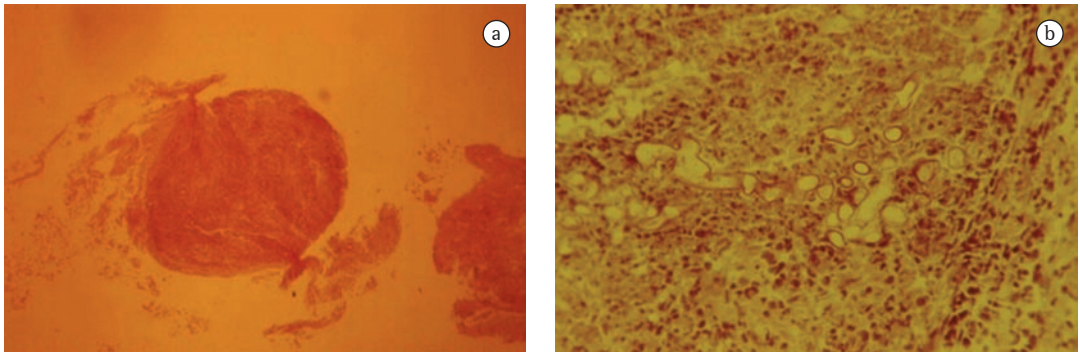


Figure 2 - Transbronchial biopsy. In a), tissue sample fragment ((H&E; magnification, $\times 10$). In b), higher magnification revealing fragments of wide and irregular Zygomycetes hyphae ((H&E; magnification, $\times 40$).

pulmonary zygomycosis are not suspected in their initial clinical presentation.⁽²²⁾ Therefore, the diagnosis of invasive mycoses requires a high degree of suspicion.⁽³⁾ The clinical and radiological presentations of zygomycosis and those of aspergillosis are similar. Culture is often negative in both. The radiologist should use invasive techniques to collect the clinical specimen. A CT scan reveals the extent of the lesion, indicates the preferential biopsy site and defines the surgical limits for lesion debridement.⁽¹³⁾

The differential diagnosis with other filamentous fungi, such as *Candida* sp., *Aspergillus* sp., *Scedosporium* sp., agents of hyalohyphomycosis and agents of phaeohyphomycosis, is made by histopathological examination. This diagnostic distinction can be made by direct immunofluorescence.⁽¹³⁾ Fragments of tissue are preferential for diagnosis, since they confirm tissue invasion. In zygomycosis, culture is indispensable for an accurate etiological characterization, since microscopy only identifies the fungal class. Agents of zygomycosis show rapid growth and

are identified by their rhizoidal, sporangiophore-like aspect, having thermal tolerance.⁽²³⁾

The development of molecular techniques, such as polymerase chain reaction, can allow earlier diagnosis in relation to conventional methods.⁽²⁾

Direct examination

Fungal elements can be found in curettage specimens of or in aspirates from material from the nose in patients with rhinocerebral disease, whereas in patients with pulmonary disease, they can be found in sputum, in bronchial aspirates and in transbronchial biopsy specimens (Figure 2). Wide, sparsely septate hyphae, branching at 90° , are seen when potassium hydroxide with Parker ink (Figure 3a) or calcofluor white is added to the material.⁽¹³⁾

Histopathology

The importance of histopathological examination is indisputable, since Zygomycetes can

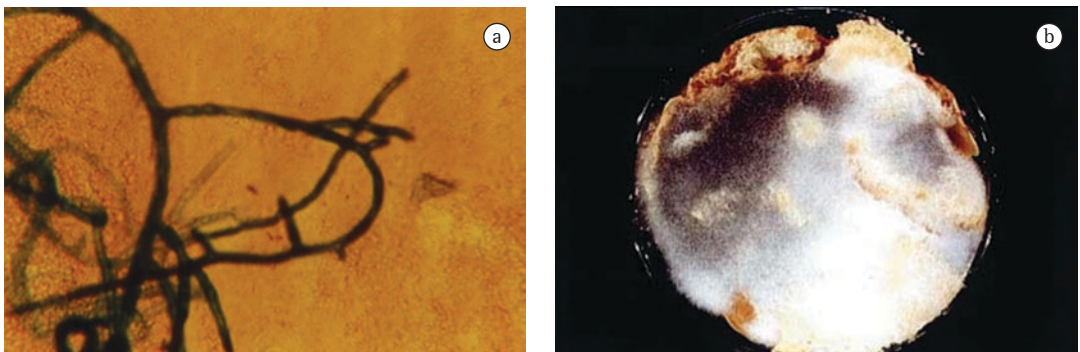


Figure 3 - Sample of bronchial aspirate. In a), hypha branched at 90° (potassium hydroxide with Parker ink; magnification, $\times 40$). In b), positive bread culture for *Rhizopus arrhizus*.

be found as contaminants in clinical samples. Different staining methods, such as H&E, can be used to observe Zygomycetes hyphae in tissue sections. However, the Grocott technique is the best method for demonstrating hyphae in tissue due to the high contrast with minimal background impregnation.⁽¹³⁾ Histopathological examination reveals tissue alterations, such as neutrophilic infiltrate, necrosis, thrombosis and septic infarction, as well as invasion of blood vessels (Figure 4).⁽²³⁾

Aspergillosis is the infection that most closely mimics zygomycosis (Table 2). Usually, these mycoses are distinguished by the hyphal morphology. However, this distinction is difficult, particularly when *Aspergillus* sp. hyphae are macerated or when the lesions contain hyphal fragments.⁽¹³⁾ There have been reports of cases of zygomycosis confirmed by culture in which the hypha was relatively uniform, with parallel borders and occasional septa. If culture had not been performed, there could have been a misdiagnosis.⁽²²⁾

Culture methods

Zygomycetes grow in standard laboratory media within 12-18 h after sample inoculation, and colony maturation occurs within 4 days, forming gray to brown cotton-like colonies.⁽²³⁾ It is difficult to establish the diagnosis based only on culture. Pathogenic species of Zygomycetes are part of the environment, are skin and saliva contaminants and grow in nearly all organic substrates.

However, an isolated organism belonging to the order Mucorales cannot be ruled out as a contaminant. The shapes and the sources that reveal the fungus should be judged critically in order to ensure the accuracy of the diagnosis. Due to the marked saccharolytic ability that these fungi have, better fungal isolation is obtained by inoculating fragments on a slice of sterilized, humidified bread (Figure 3b). Secretion, scraping and biopsy material can be inoculated on malt

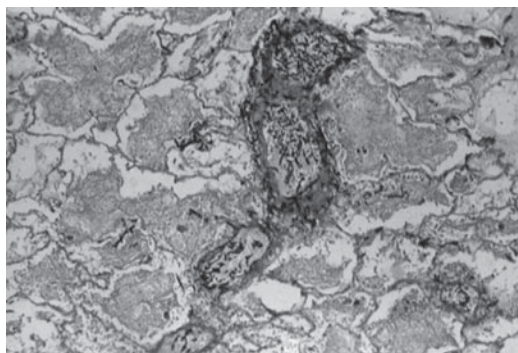


Figure 4 - Angiotropism: lung parenchyma revealing the marked angiotropism caused by Zygomycetes (Grocott; magnification, ×10).

agar, potato agar or Sabouraud agar medium and incubated at 25°C or 30°C.⁽¹³⁾ Nearly all pathogens of Mucorales are easily isolated from these materials. The culture medium should contain antibiotics for potentially contaminated specimens. However, media containing cycloheximide (Mycosel or Mycobiotic) are contraindicated due to the sensitivity of Zygomycetes to this substance.^(1,13,24)

Isolating Zygomycetes from tissue can be problematic.⁽²⁵⁾ In the literature, there are many reports of negative biopsy culture and negative autopsy culture due to maceration of the clinical specimen; since hyphae do not have septum, if there is compression, the cytoplasm will be expelled, preventing fungal growth.^(7,16)

Despite the marked angiotropism of Zygomycetes, blood culture is rarely positive, especially when using liquid culture systems.⁽²³⁾

Treatment

The successful treatment for zygomycosis involves a combined approach. Early diagnosis, prompt initiation of antifungal therapy, correction of the metabolic disorder or resolution of neutropenia are fundamental for therapeutic success (Figure 5).

Table 2 - Histomorphological characteristics of *Aspergillus* sp. and Zygomycetes.

Characteristic	<i>Aspergillus</i>	Zygomycetes
Width	Narrow (3-6 µm)	Wide (5-20 µm)
Caliber	Uniform	Varying
Branching	Regular, acute angle (dichotomous)	Random, right angle
Branching orientation	Parallel or radial	Random
Septum	Common finding	Uncommon finding

The treatment of choice is the use of amphotericin B (1.0-1.5 mg/kg/day). The total dose of amphotericin B, which has ranged from 2 to 4 g, has yet to be defined. Azole antifungal agents have no proven activity in zygomycosis, although oral posaconazole therapy seems to be promising in patients with malignant hematologic diseases and submitted to stem cell transplantation as well as in those with zygomycosis that is refractory to conventional treatment.^(13,26,27)

The use of hematopoietic stimulation factors and hyperbaric oxygen therapy can be beneficial, although data supporting routine use are still limited.⁽¹³⁾ For the patient to recover, it is important that corticosteroid therapy be reduced or discontinued.^(1,28,29)

Early surgical resection has a great impact on the evolution of mucormycosis, since the mortality rate drops from 60% to 11% in these patients.^(2,10) The surgical procedure depends on the extent of the disease and should be planned to remove all infected tissue. Lobectomy is the most common procedure, although pneumonectomy might also be necessary.^(2,10)

Empirical treatment

Unlike X-ray, CT not only reveals a greater number of nodules, but also demonstrates more characteristics of the lesions, including the halo sign. When these findings are identified in immunocompromised patients, zygomycosis and aspergillosis are the main mycoses diagnosed, and empirical treatment with amphotericin B should be strongly considered.

Voriconazole is contraindicated in the empirical treatment of zygomycosis since Zygomycetes are not sensitive to this drug. It is suggested that the increase in the number of zygomycosis infections is a result of the increase in the use of voriconazole in patients at high risk for infection with filamentous fungi (*Aspergillus* sp.).⁽⁹⁾

Preventive measures

Measures to reduce the incidence of zygomycosis in patients at risk are extremely difficult. There is no prophylactic antifungal treatment routine available, and, due to the low prevalence of zygomycosis, there is no real indication for such a routine. The most common preventive measure is environmental modifica-

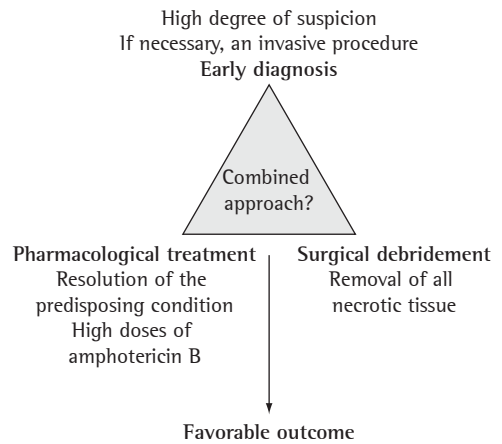


Figure 5 – Combined approach to the treatment of zygomycosis. Adapted from Gonzalez et al.⁽²¹⁾

tion in order to reduce the risk of exposure to spores in the air.

Most of these control measures focus on early identification in patients at risk, such as those with prolonged, deep neutropenia. Pre-transplant and chemotherapy rooms are isolated with high efficiency particulate air filters to treat the air, maintaining positive pressure and preventing the accumulation of dust.

Dust should be minimized in the environment of the houses of neutropenic patients. In addition, flowers and plants should be excluded from the environments due to the fact that they can contain a variety of fungal propagules.⁽⁷⁾

Prevention measures for patients other than transplant recipients or patients undergoing chemotherapy include eliminating or minimizing the predisposing conditions and the risk factors for zygomycosis. Chief among these measures are the control of diabetes, the use of binders (excluding deferoxamine), the restriction of the use of aluminum contained in hemodialysis buffer solutions and the rapid detection of the agent.⁽⁷⁾

Final considerations

Pulmonary mucormycosis is a relatively rare disease. However, with the increase in the number of immunocompromised patients, this disease can become more common. Healthy patients with some form of trauma and a history of environmental exposure can also develop this infection.

Tissue invasion by hyphae can be seen by microscopy (Grocott method) and is essential for establishing the diagnosis. However, to that end, it is necessary that knowledge on tissue presentation of filamentous fungi be mastered.

Successful management continues to be early diagnosis, followed by systemic antifungal therapy (i.v. amphotericin B) and surgical resection combined with control of the underlying disease.

References

- Prabhu RM, Patel R. Mucormycosis and entomophthoromycosis: a review of the clinical manifestations, diagnosis and treatment. *Clin Microbiol Infect.* 2004;10 Suppl 1:31-47.
- Eucker J, Sezer O, Graf B, Possinger K. Mucormycoses. *Mycoses.* 2001;44(7-8):253-60.
- Lee FY, Mossad SB, Adal KA. Pulmonary mucormycosis: the last 30 years. *Arch Intern Med.* 1999;159(12):1301-9.
- Nosari A, Oreste P, Montillo M, Carrafiello G, Draisci M, Muti G, et al. Mucormycosis in hematologic malignancies: an emerging fungal infection. *Haematologica.* 2000;85(10):1068-71.
- Funada H, Matsuda T. Pulmonary mucormycosis in a hematology ward. *Intern Med.* 1996;35(7):540-4.
- Dromer F, Mcginnis MR. Zygomycosis. In: Anaissie EJ, Pfaller MA, Mcginnis M, editors. *Clinical mycology.* New York: Churchill Livingstone; 2003. p. 297-308.
- Ribes JA, Vanover-Sams CL, Baker DJ. Zygomycetes in human disease. *Clin Microbiol Rev.* 2000;13(2):236-301.
- Severo LC, Oliveira FD, Dreher R, Teixeira PZ, Porto ND, Londero AT. Zygomycosis: A report of eleven cases and a review of the Brazilian literature. *Rev Iberoam Micol.* 2002;19(1):52-56.
- Wingard J. Zygomycosis: epidemiology and treatment options. *Johns Hopkins Adv Studies Med.* 2006;6 Suppl 6:S26-30.
- Tedder M, Spratt JA, Anstadt MP, Hegde SS, Tedder SD, Lowe JE. Pulmonary mucormycosis: results of medical and surgical therapy. *Ann Thorac Surg.* 1994;57(4):1044-50.
- Rinaldi MG. Zygomycosis. *Infect Dis Clin North Am.* 1989;3(1):19-41.
- Ascioglu S, Rex JH, de Pauw B, Bennett JE, Bille J, Crokaert F, et al. Defining opportunistic invasive fungal infections in immunocompromised patients with cancer and hematopoietic stem cell transplants: an international consensus. *Clin Infect Dis.* 2002;34(1):7-14.
- Chayakulkeeree M, Ghannoum MA, Perfect JR. Zygomycosis: the re-emerging fungal infection. *Eur J Clin Microbiol Infect Dis.* 2006;25(4):215-29.
- McAdams HP, Rosado de Christenson M, Strollo DC, Patz EF Jr. Pulmonary mucormycosis: radiologic findings in 32 cases. *AJR Am J Roentgenol.* 1997;168(6):1541-8.
- Jamadar DA, Kazerooni EA, Daly BD, White CS, Gross BH. Pulmonary zygomycosis: CT appearance. *J Comput Assist Tomogr.* 1995;19(5):733-8.
- Bouza E, Muñoz P, Guinea J. Mucormycosis: an emerging disease? *Clin Microbiol Infect.* 2006;12(Suppl 7):S7-S23.
- Murphy RA, Miller WT Jr. Pulmonary mucormycosis. *Semin Roentgenol.* 1996;31(1):83-7.
- Chamilos G, Marom EM, Lewis RE, Lionakis MS, Kontoyiannis DP. Predictors of pulmonary zygomycosis versus invasive pulmonary aspergillosis in patients with cancer. *Clin Infect Dis.* 2005;41(1):60-6.
- Severo LC. Diagnostico radiologico. In: Palacio A, Pontón J, Guarro J, Quindós G, editors. *Guia de bolsillo: Zigomicosis invasoras.* Bilbao: Rev Iberoam Micol; 2008. p. 59-63.
- Gollard R, Rabb C, Larsen R, Chandrasoma P. Isolated cerebral mucormycosis: case report and therapeutic considerations. *Neurosurgery.* 1994;34(1):174-7.
- Gonzalez CE, Rinaldi MG, Sugar AM. Zygomycosis. *Infect Dis Clin North Am.* 2002;16(4):895-914, vi.
- Freifeld AG, Iwen PC. Zygomycosis. *Semin Respir Crit Care Med.* 2004;25(2):221-31.
- Chandler FW, Watts JC. Zygomycosis. In: Connor DH, Chandler FW, editors. *Pathology of infectious diseases.* Stamford: Appleton & Lange; 1997. p. 1113-9.
- Kwon-Chung KJ, Bennett JE. Mucormycosis. In: Kwon-Chung KJ, Bennett JE. *Medical Mycology.* Philadelphia: Lea & Febiger; 1992. p. 524-59.
- Bigby TD, Serota ML, Tierney LM Jr, Matthay MA. Clinical spectrum of pulmonary mucormycosis. *Chest.* 1986;89(3):435-9.
- Greenberg RN, Mullane K, van Burik JA, Raad I, Abzug MJ, Anstead G, et al. Posaconazole as salvage therapy for zygomycosis. *Antimicrob Agents Chemother.* 2006;50(1):126-33.
- Rogers TR. Treatment of zygomycosis: current and new options. *J Antimicrob Chemother.* 2008;61 Suppl 1:i35-40.
- Parfrey NA. Improved diagnosis and prognosis of mucormycosis. A clinicopathologic study of 33 cases. *Medicine (Baltimore).* 1986;65(2):113-23.
- Kauffman CA. New antifungal agents. *Semin Respir Crit Care Med.* 2004;25(2):233-9.

About the authors

Cecília Bittencourt Severo

Doctoral Student. Postgraduate Program in Pulmonology, *Universidade Federal do Rio Grande do Sul* – UFRGS, Federal University of Rio Grande do Sul – Porto Alegre, Brazil.

Luciana Silva Guazzelli

Doctoral Student. Postgraduate Program in Pulmonology, *Universidade Federal do Rio Grande do Sul* – UFRGS, Federal University of Rio Grande do Sul – Porto Alegre, Brazil.

Luiz Carlos Severo

Associate Professor. Department of Internal Medicine, *Universidade Federal do Rio Grande do Sul* – UFRGS, Federal University of Rio Grande do Sul – Porto Alegre, Brazil.