



Managing breathlessness in end-stage COPD: a neural respiratory drive approach

Neeraj M Shah^{1,2}, Nicholas Hart^{1,2}, Georgios Kaltsakas^{1,2}

BACKGROUND

Management options for patients with COPD with persistent breathlessness can range from non-pharmacological, to pharmacological, to mechanical interventions. This case discusses a patient with severe COPD who was referred for lung transplantation; however, he was eventually managed with daytime non-invasive ventilation (NIV).

CASE HISTORY

A 47-year-old gentleman with severe bullous emphysema (FEV₁: 0.48 L; 11% of predicted; FVC: 1.71 L; 32% of predicted) was referred by his respiratory team for consideration for lung transplantation. He had a smoking history of 30 pack-years including heavy cannabis use in the past. He had suffered from four exacerbations requiring hospitalisation in the past twelve months. He was alpha-1 antitrypsin negative. He also suffered from osteoporosis and chronic hip pain. He had experienced pathological rib fractures secondary to coughing. At the time of referral he was using inhaled long-acting β_2 -agonist+corticosteroid, an inhaled long-acting muscarinic antagonist, amitriptyline, regular morphine and breakthrough morphine for breathlessness. He used nocturnal NIV. Baseline arterial blood gas analysis revealed pH = 7.38; PaO₂ = 9 kPa; PaCO₂ = 7.1 kPa; and HCO₃⁻ = 31 mmol/L. He had severely impaired mobility and is a nursing home resident at this writing. The transplant team felt that, considering his poor nutritional state, deconditioning and lack of social support, he was unlikely to have a positive outcome after lung transplantation. He was referred by the transplant team to the regional ventilation centre for consideration of high-flow nasal cannula (HFNC) therapy for management of breathlessness. He underwent a clinical respiratory physiology assessment.

CLINICAL RESPIRATORY PHYSIOLOGY ASSESSMENT

The patient was seen in our ventilation centre for consideration of HFNC therapy. He underwent a full respiratory physiology assessment including measurement of spirometry, respiratory muscle strength and parasternal electromyogram, a surrogate biomarker of neural respiratory drive.⁽¹⁾ The neural respiratory drive index (NRDI) is the product of the neural respiratory drive and the respiratory rate. In this patient, NRDI was increased at baseline (normal value: 74 [46-144] %breaths/min).⁽²⁾ He was assessed during quiet breathing, and then

initiated on HFNC at 20 L/min. This was increased to 60 L/min in increments of 10 L/min. He was then assessed on NIV. The patient's parasternal electromyogram was recorded throughout this titration, and he was asked to score his dyspnoea using the modified Borg Dyspnoea Scale. Breath-by-breath analysis of the parasternal electromyogram was performed. ANOVA followed by Tukey's post hoc test demonstrated that NRDI significantly decreased at each HFNC flow except at 20 L/min. NRDI was significantly reduced on NIV compared with any HFNC flow (Figure 1). Interestingly, the modified Borg Dyspnoea Scale score was 1 at baseline and at each HFNC flow, but 0 with the use of NIV.

DISCUSSION

In patients with end-stage COPD, in whom lung transplantation is not a viable option, the clinical priority is

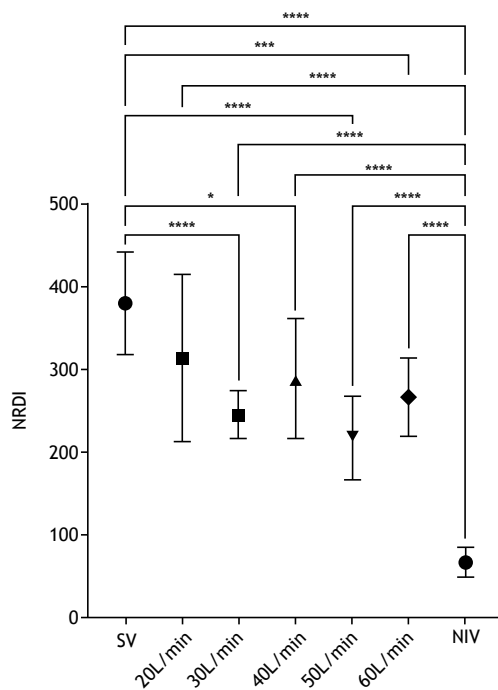


Figure 1. Neural respiratory drive index (NRDI) displayed during spontaneous ventilation (SV), at increasing flows of high flow nasal cannula (from 20 L/min to 60 L/min) and during non-invasive ventilation (NIV). For each setting, breath-by-breath data from one minute of stable parasternal electromyogram is displayed, as mean \pm SD. *p < 0.05; ***p < 0.001; ****p < 0.0001.

1. Lane Fox Clinical Respiratory Physiology Centre, Guy's and St Thomas' NHS Foundation Trust, London, United Kingdom.
2. Centre for Human and Applied Physiological Sciences-CHAPS-King's College London, London, United Kingdom.

to manage breathlessness and prevent hospitalisations. Patients often remain breathless despite opiate use. HFNC, an increasingly available intervention, has been recommended for treatment of breathlessness, but the evidence to support this in end-stage hypercapnic COPD patients is limited.⁽³⁾ Increased neural respiratory drive has been associated with an increased perception of breathlessness,⁽⁴⁾ and so interventions that lower neural respiratory drive may be useful in treating breathlessness. Parasternal electromyogram is a useful, non-invasive biomarker of neural respiratory drive.⁽¹⁾ Despite increasing flows on HFNC, NRDI did not change. On daytime NIV, his NRDI decreased considerably, and this was associated with a decrease in subjective breathlessness. Although HFNC has many potential applications in both hypoxic and hypercapnic respiratory failure, in this case, it failed to improve NRDI, suggesting that it does not have an impact on offloading the respiratory muscles. In contrast, NIV has been demonstrated to offload respiratory muscles; thus, reducing the work of breathing.⁽⁵⁾ This is the

likely explanation for the improvement in breathing after initiation of NIV in this patient.

CLINICAL MESSAGE

Assessment of neural respiratory drive can be a useful tool in clinical practice. Non-pharmacological interventions in combination with standard pharmacological therapy may decrease neural respiratory drive and improve symptoms in patients with end-stage chronic respiratory disease. Clinicians should consider using daytime NIV and HFNC in patients with refractory breathlessness, utilizing their positive impact on neural respiratory drive at rest.

AUTHOR CONTRIBUTIONS

Each author contributed equally to study conception, study design, data collection, data analysis, data synthesis and writing of the manuscript.

CONFLICTS OF INTEREST

None declared.

REFERENCES

1. Murphy PB, Kumar A, Reilly C, Jolley C, Walterspercher S, Fedele F, et al. Neural respiratory drive as a physiological biomarker to monitor change during acute exacerbations of COPD. *Thorax*. 2011;66(7):602-608. <https://doi.org/10.1136/thx.2010.151332>
2. MacBean V, Hughes C, Nicol G, Reilly CC, Rafferty GF. Measurement of neural respiratory drive via parasternal intercostal electromyography in healthy adult subjects. *Physiol Meas*. 2016;37(11):2050-2063. <https://doi.org/10.1088/0967-3334/37/11/2050>
3. D'Cruz RF, Hart N, Kaltsakas G. High-flow therapy: physiological effects and clinical applications. *Breathe (Sheff)*. 2020;16(4):200224. <https://doi.org/10.1183/20734735.0224-2020>
4. Jolley CJ, Luo YM, Steier J, Rafferty GF, Polkey MI, Moxham J. Neural respiratory drive and breathlessness in COPD. *Eur Respir J*. 2015;45(2):355-364. <https://doi.org/10.1183/09031936.00063014>
5. Khilnani GC, Banga A. Noninvasive ventilation in patients with chronic obstructive airway disease. *Int J Chron Obstruct Pulmon Dis*. 2008;3(3):351-357. <https://doi.org/10.2147/copd.s946>